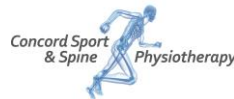

Lower Leg Pain

For information on all types of injuries visit:
<http://www.cssphysio.com.au/Doctors/forDoctors.html>



Lumbar Stress Fractures in Fast Bowlers

Anatomy

Lumbar stress fracture injuries are typified by gradual onset, and most commonly occur at the L4/L5 pars interarticularis, on the non-dominant side. They are seen more frequently in adolescents due to a combination of skeletal immaturity, increase in loading and biomechanical factors. It is a complex and challenging injury to prevent, diagnose and treat.

Lumbar stress fractures are responsible for the most game-time lost in elite cricketers over a season (1) and are almost exclusively found in the fast bowling population. The mechanics of a bowling action involve high impact rotation, extension and lateral flexion (2), all of which place great force and strain through the facets and in turn the pars interarticularis. Given that anatomically the pars has the smallest cross sectional area of cortical bone, this makes it the weak link in the chain of force absorption. Technique and biomechanical impairments or faults in the bowling action exaggerate this force (2). When combined with hard playing surfaces (3), this becomes a recipe for injury and hence these are two major factors in the development of bone stress in our athletes.

Diagnosis

The diagnosis of stress fractures is made through clinical assessment and confirmed through MRI imaging of the lumbar spine. Clinically, patients will present with a recent increase in workload of primarily bowling (3), but also running, gym lifting or rowing. This 'recent' increase in workload may be up to 1-2 months previous as asymptomatic bone stress response will have developed previously and only recently become symptomatic (4). On physical assessment there will be.

- 1) localized one sided pain, on the non-dominant side.
- 2) Soreness on palpation through the area and possible muscle spasm.
- 3) Pain on extension and rotation movements.
- 4) Pain on prolonged standing, relieved in sitting or slumped positions.

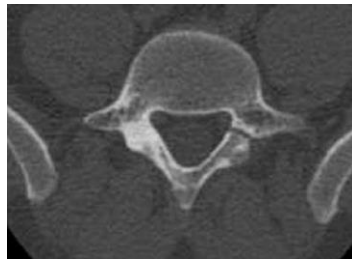
If stress fracture is suspected, initial management should commence and MRI imaging sought.

Imaging

MRI is the preferred option, especially in the adolescent cricketer, as over the career of a fast bowler, literature strongly suggests recurrence (5),

and hence the need to limit radiation exposure. Currently MRI scanning with the 'stress fracture protocol' at PRP imaging in Moore park, with reporting via Dr Phil Lucas being considered the gold standard.

MRI does not just confirm or rule out the presence of a fracture. Bony stress reaction, pars defects and spondylolystheis can be differentially diagnosed from the scan, and have different treatment directions. MRI scans are performed both initially, and at week 4 to confirm no increase in bone signal, or increase in fracture as can sometimes occur due to the nature of the bone remodeling process, i.e. reabsorption and new matrix formation (6). Only when the second MRI is seen and been confirmed that there has been no progression in the fracture can management progress.



MRI image demonstrating defect of the right pars interarticularis, with bone stress on the left

Management

Protocol for management undergoes 5 distinct phases, (7)

1. From the moment stress fractures are suspected, complete rest from all activities including running and rotation / extension activities for the first 4 weeks.
2. Progressive core stabilization exercises and posture education
3. Upper and lower limb conditioning without impact.
4. Progressive return to play running program
5. Graduated return to play bowling program and technique correction.

The expected return-to-play timeline for a typical case would be 26 weeks.

References

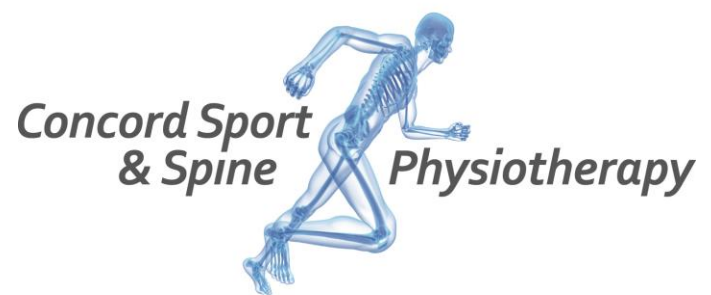1. Orchard J, et al, "Injuries in Australian cricket at first class level 1995/1996 to 2000/2001."
2. Portus M, et al, "Cricket fast bowling performance and technique and the influence of selected physical factors during an 8 over spell"
3. Warden S, Et al, "Stress fractures: pathophysiology, epidemiology and risk factors"
4. Orchard J, "Fast bowlers in cricket demonstrate upto 3-4 weeks delay between workload and increased risk of injury"
5. Johnson M, et al, "Lumbar vertebral stress injuries in fast bowlers: A review of prevalence and risk factors"
6. Kalfas H, "Principals of bone healing"
7. Debnath U, Et al "Lumbar pars injury or spondylolysis – diagnosis and management"

For information for doctors on physiotherapy management of all types of injuries visit:

<http://www.cssphysio.com.au/Doctors/fordocors.html>

Information for patients is at:

<http://www.cssphysio.com.au/forpatients.html>



[Concord Sport & Spine Physiotherapy](http://www.cssphysio.com.au)
202 Concord Road
Concord West, NSW 2138
Sydney, Australia.

Ph (02) 9736 1092

Email: info@cssphysio.com.au

Web: www.cssphysio.com.au